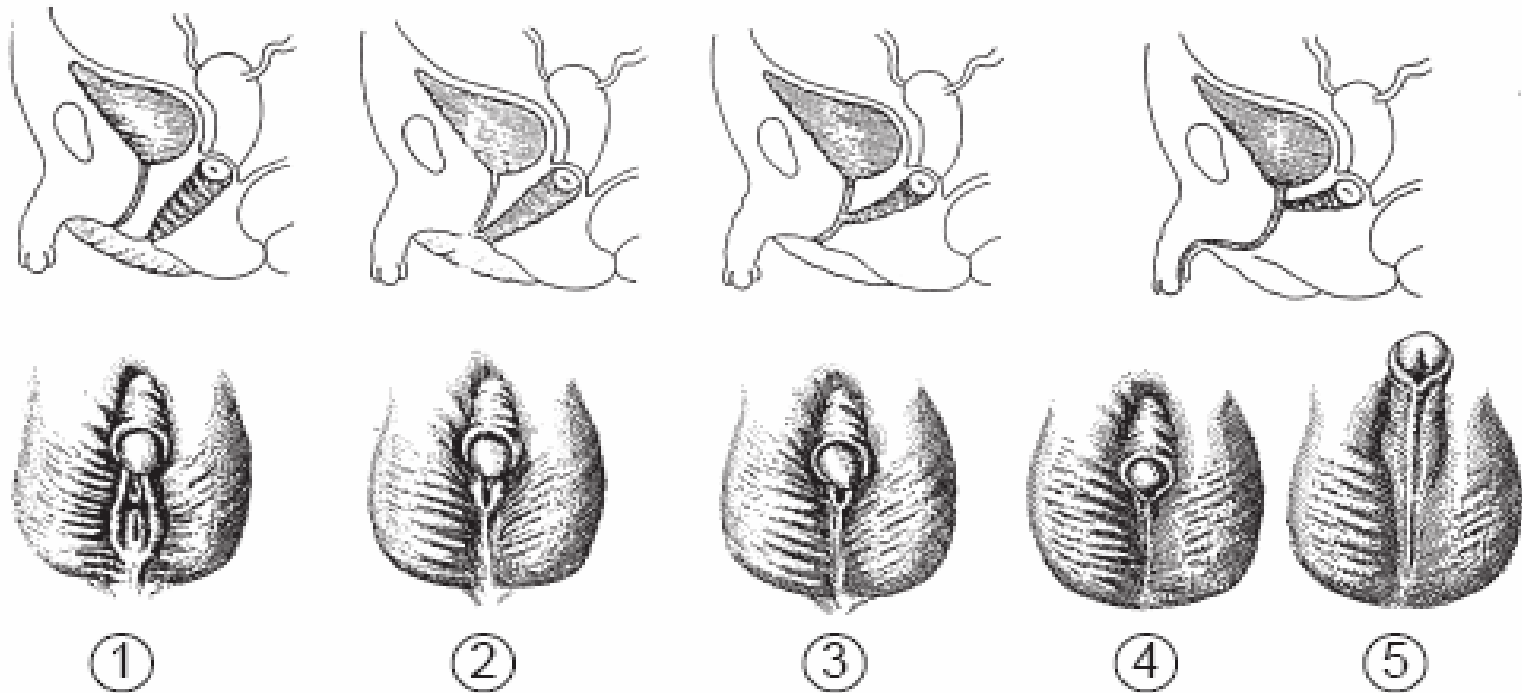


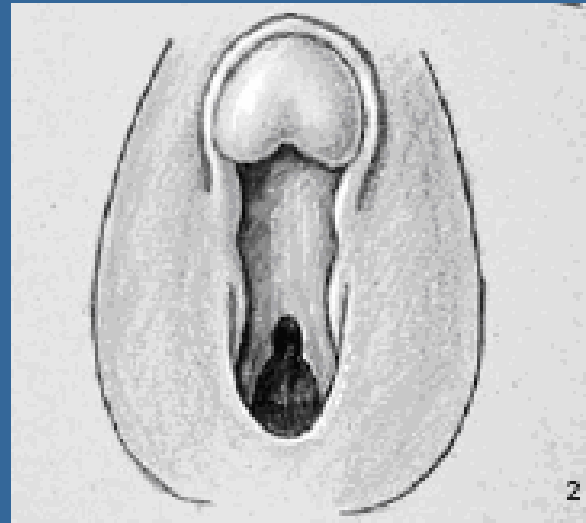
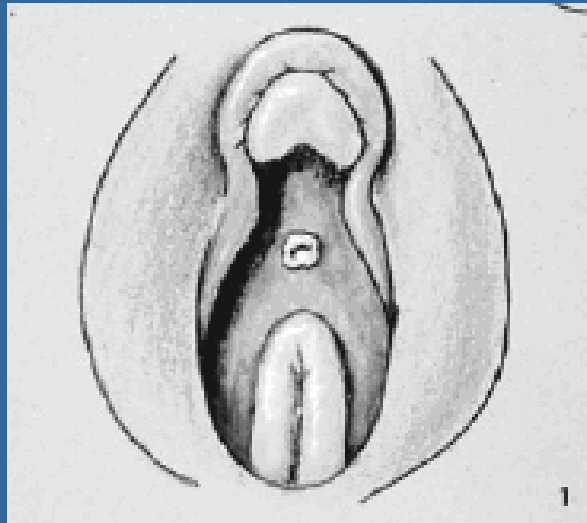
## METHODS AND MATERIALS

- ANATOMICAL CLASSIFICATION OF VIRILIZATION  
(PRADER).



## METHODS AND MATERIALS

- ANATOMICAL CLASSIFICATION OF VIRILIZATION  
(PRADER).

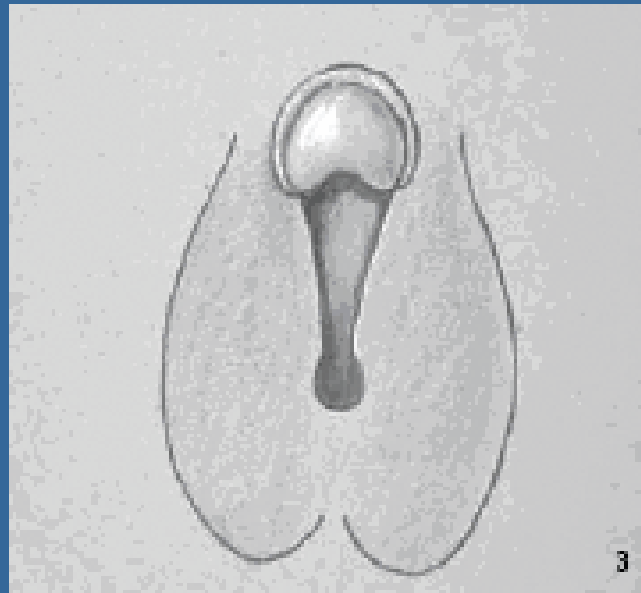


**I.** Female external genitalia with clitoromegaly.

**II.** Clitoromegaly with partial labial fusion forming a funnel-shaped urogenital sinus.

## METHODS AND MATERIALS

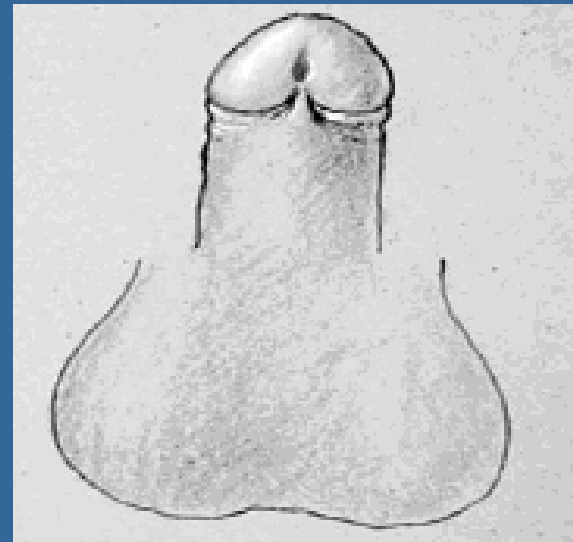
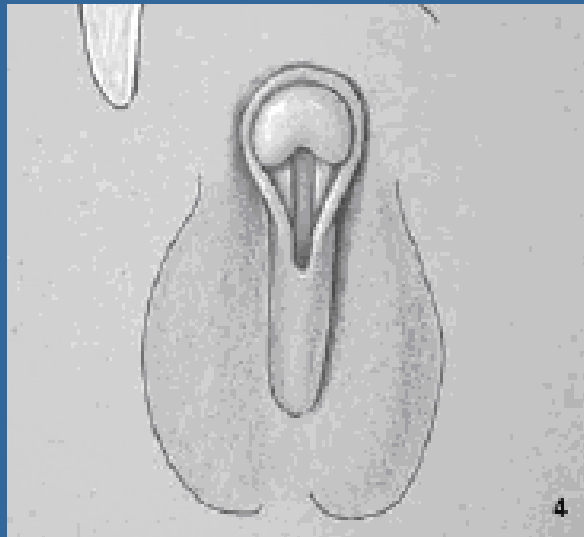
- ANATOMICAL CLASSIFICATION OF VIRILIZATION  
(PRADER).



III. Increased phallic size with complete labioscrotal fusion forming a urogenital sinus with a single opening.

## METHODS AND MATERIALS

- ANATOMICAL CLASSIFICATION OF VIRILIZATION  
(PRADER).



**IV.** Complete scrotal fusion with the opening of the urogenital sinus at the base of the phallus.

**V.** Normal male external genitalia.